

U of M Horse Newsletter

Providing research-based information to Minnesota Horse Owners

Visit our Website at: www.extension.umn.edu/horse for more information and to subscribe to the newsletter.

Volume 7, Issue 9

September 2011



Equine Protozoal Myeloencephalitis

Neurologic diseases are often challenging for horse owners and veterinarians. Symptoms range from slight lameness to drastic behavioral or physical changes. Early recognition of clinical symptoms of neurologic disease is important for effective treatment.

Equine protozoal myeloencephalitis (EPM) is a neurologic disease commonly diagnosed in horses. This disease is caused by *Sarcocystis neurona*. The opossum is the main host of this parasite. Opossums carrying *S. neurona* shed encysted eggs in their feces. This encysted form allows the eggs to persist in the environment, where they are ingested by horses from contaminated food or water. *S. neurona* then localizes in the brain and spinal cord of infected horses causing inflammation and degeneration.

Neurological signs of EPM are dependent on the location of the inflammation within the central nervous system. When EPM affects the spinal cord, common signs include muscle loss (generally asymmetric and involving the hindquarters), in-coordination or stumbling, and weakness or spastic (stilted) gait. When EPM involves the brain, symptoms may include a head tilt, difficulty swallowing, deviation of the muzzle to one side, or drooping of an ear. The disease can progress to severe in-coordination, blindness, seizures and behavioral changes.

EPM is usually diagnosed by the presence of asymmetric neurologic disease combined with evidence of antibodies in a blood or cerebrospinal fluid (CSF) sample. Diagnosis of EPM may also involve testing and eliminating other diseases as the cause of the neurologic symptoms. Effective vaccines for EPM are not yet available. Early recognition and prompt treatment of EPM will increase the horse's chance of recovery. Horses that receive treatment are ten times more likely to show improvement and are fifty times less likely to die.

Reducing exposure of the horse to opossum feces is the mainstay of EPM prevention. Storage of feed in opossum-proof containers, such as chest freezers or lockable garbage cans, is important in preventing fecal contamination. Protection of bedding and use of shavings may reduce exposure to opossum feces, as well. Regular veterinary care, minimizing stress, and a moderate exercise schedule can help maintain a healthy immune system to protect against a protozoal infection. Removal of dead animal carcasses from the property and roadsides will help prevent attraction of opossum to the farm.

Authors: Kate Baer and Hannah Daigle, Univ. of Minn. Veterinary Students

Ask the Expert—Maple Toxicity

By: K. Martinson, PhD, U of M

Q: There are several hybrid maple trees being sold at Nurseries. The hybrids are half Silver Maple and half Red Maple. Have any studies been done on the toxicity of these hybrids to horses?

A: All trees in the maple family (*Acer* species) are considered toxic, including hybrids. However, the toxicity is only associated with **WILTED** maple leaves (i.e.

in the fall or after a storm). Assuming your horse has sufficient forage (hay or pasture), ingestion of enough wilted leaves to cause toxicity is unlikely, however, cases have occurred in the fall or during a drought when pasture forage is limited. For more information on maple toxicity, visit:

www.extension.umn.edu/horse/components/poisonousplants.htm

Inside This Issue

EPM	1
Ask the Expert	1
Conformation Cont.	2
Research Update	2

Upcoming Events

The University of Minnesota is an equal opportunity employer and educator.

Webinar

Reducing Hay Waste
By Dr. K. Martinson
Tuesday, September 27
at 6 pm (central)

To register (free):

www.myhorseuniversity.com/node/559

Advanced Horse Owner Program

October 15, 2011
St. Paul Campus
To register (\$25):

www.regonline.com/AdvancedHorse

Quarterly Lunch and Learn Webinar

EMS in Ponies
By Dr. Nick Frank
Tuesday, October 18th
at 6:00 pm (central)

To register (free):

www.myhorseuniversity.com/node/560

Horse Owner Education Program

November 12, 2011
UM—Crookston Campus

Draft Horse Owner Education Program

February 18, 2012
St. Paul Campus

Four State Equine Business Conference

February 25, 2012
St. Paul Campus



Conformation: Form to Function Cont.

By: ADawn Melbye, U of M - Crookston

Divide the horse into three parts; first from point of chest to just behind heart girth (chest), second from behind the heart girth to point of hip (back), and third from point of hip to point of buttock (croup) (see figure).

The shape of the horse's chest is an important part of its stamina and endurance. Chest conformation also determines lung capacity. Many horses have 18 pairs of ribs, but may range from 19 to 17 with the exceptions being Thoroughbreds and Arabians. Extra ribs allow for a shorter lumbar vertebrae area which results in stronger "coupling" of the loin area. The loin is the muscle portion of the back behind the saddle, typically from the last rib, to the point of the croup.

The underline of the horse should rise gradually to the hindquarters. Horses that have "spring of rib" have ribs that project outward, have large spaces between the ribs, are shorter backed and have a strong loin. A wide chest shape is favored by most horsepersons. From the front, a wide chest allows for lung expansion, which allows for greater endurance and more room for muscle attachment. The better

combination of ribs and chest, the stronger the attachment of legs, shoulders and neck with the rest of the body which creates a powerful athletic performer.

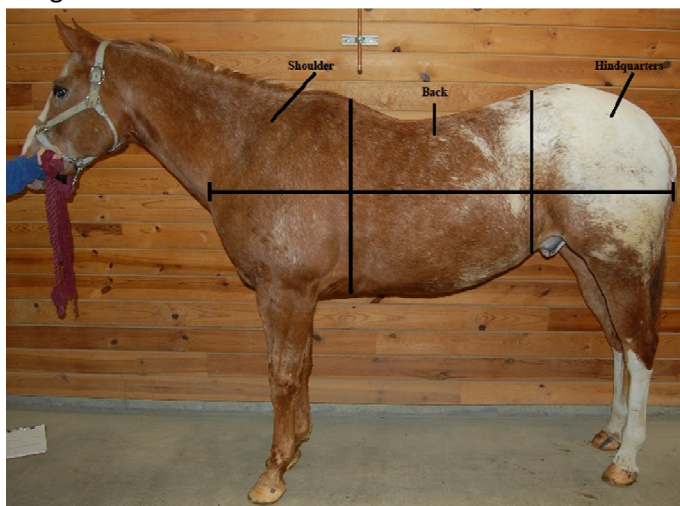
The horses back must be functional and withstand the stress of work. The back transmits the force and driving power from the hind legs. A horse should have well formed withers that allow for attachment of the shoulder to the rest of the horses body. The length of the horses back can be measured from the middle of the withers to the point of hip. This should be one third the length of the horse. A horse's back should be longer than their underline.

A horse with a long neck and short back provides the best maneuverability of head and neck, while the short back allows strength for carrying the weight of the rider.

Towards the rear of the horses back is the croup. This is the highest point of the rump. The croup helps with

the transmission of energy for thrust and power in the hind end of the horse. Croup height should not be too high, but rounded with muscle to provide a smooth contoured shape. The croup should be at the same height when compared to the withers to maintain balance in the horses overall confirmation. The quarters are positioned below the croup. When viewing the quarters, they should not be too sloped or too flat. The length of the quarter can be measured form the point of the horse's hip to point of buttock. This length should be about 1/3 of the horse's body length using the proportions as described above.

Our series on conformation continues next month.



Research Update—Slowing Grain Consumption

The rapid intake of grain diets high in soluble carbohydrates can result in increased blood insulin and possible problems with insulin sensitivity and laminitis. Simply slowing feed consumption may reduce blood insulin levels. This was the objective researchers from North Carolina State University set out to investigate.

To investigate the time of grain

consumption, four treatments were evaluated: 1) a control; 2) adding four bocce balls to the grain bucket; 3) inserting a waffle-type plate at the bottom on the grain bucket; and 4) wetting down the grain prior to feeding. Time of grain consumption and post-feeding blood insulin samples were taken.

The bocce balls and waffle insert increased time to feed consumption

compared to the control and wetted feed. The bocce ball treatment also reduced the concentration of blood insulin compared to all other treatments.

The use of obstacles in a feed bucket effectively increased feed intake time, which resulted in decreased insulin concentrations post-feeding. *Summarized by K. Martinson, PhD, U of M*